6. Swanson E. The questionable role of antibiotic irrigation in breast augmentation. *Plast Reconstr Surg.* 2019;144:249–252.
7. Kim JYS, Davila AA, Persing S, et al. A meta-analysis of human acellular dermis and submuscular tissue expander breast reconstruction. *Plast Reconstr Surg.* 2012;129:28–41.
8. Swanson E. Concerns regarding the use of acellular dermal matrix at the time of primary breast augmentation. *Ann Plast Surg.* 2021;86:1–2.
9. Kornstein AN. The benefit of acellular dermal matrix placement in primary breast surgery may outweigh the cost in patients at high risk of capsular contracture. *Aesthet Surg J.* 2020;40:NP434–NP435.
10. Wagner DS, Mirhaidari SJ. Capsulectomy, implant exchange, and placement of acellular dermal matrix is effective in treating capsular contracture in breast augmentation patients. *Aesthet Surg J.* 2021;41:304–312.

Reply: Surgical Treatment for Capsular Contracture: A New Paradigm and Algorithm

Let us begin by saying Dr. Swanson is our favorite plastic surgery iconoclast whom we respect and admire for his many provocative theories challenging conventional wisdom. Although we agree with many of his alternative viewpoints, we completely disagree with this particular one.

While the acellular dermal matrix group was a small subset of the study population, a success rate of 97 percent is inarguable proof of its effectiveness. This has been further proven to us beyond a doubt as our series has grown substantially since completion of our study.[1]

Despite Dr. Swanson admirably referencing every statement to add support to his position, we submit that more than 30 years of clinical experience provides equal authority. With that, we reject the notion that a capsulotomy causes a meaningful difference in morbidity compared with a capsulectomy. Expertly performed capsulectomies do not remove any meaningful amount of breast tissue, even in those who have little to begin with. Capsulectomy requires only an extra half hour and a drain compared to capsulotomy, well worth the greater efficacy that most of the literature substantiates.

Capsulectomies replaced capsulotomies long ago because of the high failure rate of the latter. As with the current revival of prepectoral augmentation, we seem doomed to repeat our history if we do not know it, as the saying goes.

We would argue that capsulectomy has an aesthetic benefit as well. Optimal breast shape is restored by removal of the anterior capsule and lysis of the adjacent pericapsular adhesions.

Revisional surgery with acellular dermal matrix is more technically challenging, but it is easily mastered after a few cases. It's not free flap surgery. In addition, morbidity has not proven greater than with capsulectomy alone in our practice. Given the size of breast implants as "avascular products," adding a 25-cc volume of acellular dermal matrix as another is meaningless.

Cost and longer operating time are correctly pointed out as drawbacks to the use of acellular dermal matrix. That is why we do not advocate its use loosely, but instead have developed a precise algorithm that mitigates these disadvantages while minimizing the prospect of contracture recurrence. Implants are a lifetime financial commitment for patients, and it is our responsibility to make sure they know this before their first procedure. Interestingly, "pharma" could make it easier on our patients given that a piece of acellular dermal matrix costs only about $100 to produce (Steven Fagien, M.D., personal communication, November 11, 2019). In any event, at least we now have a solution for one of our most vexing problems that otherwise leads to patient frustration and anger with each repeated failure using conventional treatment without acellular dermal matrix.

Finally, we believe that Dr. Swanson's concerns regarding the safety of acellular dermal matrix are overstated. We still await the first case report arguing otherwise. Regarding his question about using this material in a family member, we would not hesitate to do so if needed.

In closing, we enjoyed Dr. Swanson's stimulating letter and look forward to his next critical examination of current practices in our specialty!

DOI: 10.1097/PRS.0000000000008344

David Hidalgo, M.D.

Andrew Weinstein, M.D.
Weill-Cornell Medical College
New York, N.Y.

Correspondence to Dr. Hidalgo
Weill-Cornell Medical College
655 Park Avenue
New York, N.Y. 10065
www.drdavidhidalgo.com
Intagram: @drdavidhidalgo

DISCLOSURE

Neither of the authors has any financial disclosures with respect to the contents of this communication.

REFERENCE

1. Hidalgo DA, Weinstein AL. Surgical treatment for capsular contracture: A new paradigm and algorithm. *Plast Reconstr Surg.* 2020;146:516–525.

The Nonsurgical Rhinoplasty: A Retrospective Review of 5000 Treatments

We have read with great interest the article "The Nonsurgical Rhinoplasty: A Retrospective Review of 5000 Treatments," recently published in the *Journal* by Harb and Brewster.[1] The authors

presented the experience of a single clinician performing nonsurgical rhinoplasty in the largest cohort to date, 5000 patients undergoing hyaluronic acid injection to correct a large number of aesthetic concerns.

We would like to congratulate the authors on their article—the topic that they focused on is extremely important for all the surgeons dedicated to nonsurgical rhinoplasty—as well as on their surgical approach. We agree with the authors that nonsurgical rhinoplasty can be a highly satisfying treatment for both patient and clinician for primary correction as well as for postrhinoplasty sequelae that can easily be treated without surgery.

In our experience, a patient's nasal skin thickness is crucial to determine the cosmetic outcome of rhinoplasty and thus patient satisfaction. In our already-published study,[2] we underlined that the thin-skinned patients who did not undergo camouflage of the nasal dorsum during surgical rhinoplasty were the most dissatisfied and underwent an increased number of secondary procedures. In thin-skinned patients, therefore, we must consider performing an ancillary procedure that covers the cartilage grafts and flaps in order to harmonize the results. Diced cartilage is one of the most widely used camouflage techniques in rhinoplasty, as first described by Peer in the 1943.[3] When we did not preoperatively plan for camouflage of the dorsum in thin-skinned patients, we could observe contour deformities sometimes associated with loss of the continuity of the Shean-line dorsum.

We present the case of a 35-year-old woman with a very thin envelope of the nasal region who had undergone primary closed rhinoplasty 7 years earlier. At that time, we had not yet begun performing dorsum camouflage during rhinoplasty. During the postoperative follow-up, we discussed with the patient the possibility of correcting the contour deformity with a surgical revision; the patient refused to undergo to a new operation, so we proposed a nonsurgical rhinoplasty. We infiltrated 1 cc of Juvederm Voluma Lidocaine (2 × 1 ml) (Allergan, Irvine, Calif.), with 0.1 cc at the radix of the nose, 0.5 cc at the dorsum site, 0.15 cc at the tip level, and 0.25 cc in the columellar region. With this technique, we restored the symmetry of the nasal region and achieved a satisfactory result for the patient and the surgeon (Fig. 1). We consider nonsurgical rhinoplasty to be a versatile tool after rhinoplasty as well, in thin-skinned patients who refuse to undergo revision surgery. [**See Figure, Supplemental Digital Content 1**, which shows 7-year postrhinoplasty result (*above, left to right*: frontal, oblique, profile, and basal views) and 2-month post–nonsurgical rhinoplasty result (*below, left to right*: frontal, oblique, profile, and basal views), ***http://links.lww.com/PRS/E621***.]

DOI: 10.1097/PRS.0000000000008345

Mauro Barone, M.D.

Annalisa Cogliandro, M.D., Ph.D.

Paolo Persichetti, M.D., Ph.D.
Plastic and Reconstructive Surgery Department
Campus Bio-Medico University of Rome
Rome, Italy

Correspondence to Dr. Cogliandro
Via Alvaro del Portillo 200
Rome 00128, Italy
a.cogliandro@unicampus.it

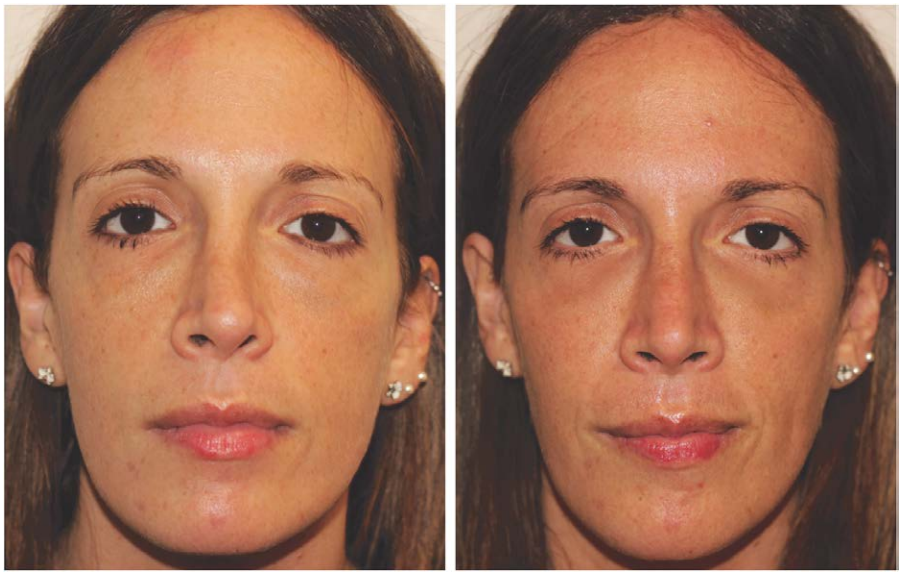

Fig. 1. (*Left*) Seven-year postrhinoplasty result. (*Right*) Two months after nonsurgical rhinoplasty.

PATIENT CONSENT

Patient provided written consent for the use of her images.

ACKNOWLEDGMENT

Authors are members of the research group "To be and to appear: Objective indication to Plastic Surgery" of Campus Bio-Medico University of Rome, in Rome, Italy.

DISCLOSURE

The authors have no commercial associations that might pose or create a conflict of interest with information presented in this communication. No intramural or extramural funding supported any aspect of this work.

REFERENCES

1. Harb A, Brewster CT. The nonsurgical rhinoplasty: A retrospective review of 5000 treatments. *Plast Reconstr Surg.* 2020;145:661–667.
2. Barone M, Cogliandro A, Salzillo R, et al. The role of skin thickness in the choice of a rhinoplasty technique for thin-skinned patients: Analysis of long-term results and patient satisfaction. *Aesthetic Plast Surg.* Published ahead of print May 14, 2020.
3. Peer AL. Diced cartilage grafts. *Arch Otolaryngol.* 1943;38:156.

Quality and Quantity–Cultured Human Mononuclear Cells Improve Human Fat Graft Vascularization and Survival in an In Vivo Murine Experimental Model

We read with great interest the article entitled "Quality and Quantity–Cultured Human Mononuclear Cells Improve Human Fat Graft Vascularization and Survival in an In Vivo Murine Experimental Model," by Geeroms et al.[1] The authors confirmed that quality and quantity–cultured human mononuclear cells improve fat graft survival through enhancing vascularization in vivo.

In this study, the authors used a new formula for cell culture, which can promote vascularization. The culture with serum-free medium contained stem cell factor, thrombopoietin, vascular endothelial growth factor, interleukin-6, and Flt-3 ligand.[2] We wonder whether this mixture containing multiple nutrients can be understood as a new medium that can promote cell proliferation and secretion. What types of cells are this new medium suitable for, other than mononuclear cells[1] and endothelial progenitor cells?[3] Furthermore, although the authors found that quality and quantity–cultured cells promote fat survival, there is still a distance from clinical transformation due to the addition of multiple items for the sake of security.

The fat grafts were explanted at 7 weeks for analyses. However, 8 weeks is a more recognized extraction time, since the graft volume and vasculature stabilize after 8 weeks.[4]

DOI: 10.1097/PRS.0000000000008346

Zuguang Hua, M.D.
Peng Wei, M.D.
Ningbo No. 1 Hospital
Zhejiang, People's Republic of China

Correspondence to Dr. Hua
Ningbo No. 1 Hospital
No. 59, Liuting Street
Haishu District
Ningbo 315000, Zhejiang, People's Republic of China
hzg-m2004@126.com

DISCLOSURE

The authors have no financial interest to declare in relation to the content of this communication. No funding was received for this communication.

REFERENCES

1. Geeroms M, Fujimura S, Aiba E, et al. Quality and quantity–cultured human mononuclear cells improve human fat graft vascularization and survival in an in vivo murine experimental model. *Plast Reconstr Surg.* 2021;147:373–385.
2. Masuda H, Iwasaki H, Kawamoto A, et al. Development of serum-free quality and quantity control culture of colony-forming endothelial progenitor cell for vasculogenesis. *Stem Cells Transl Med.* 2012;1:160–171.
3. Geeroms M, Hamdi M, Hirano R, et al. Quality and quantity-cultured murine endothelial progenitor cells increase vascularization and decrease fibrosis in the fat graft. *Plast Reconstr Surg.* 2019;143:744e–755e.
4. Jin S, Yang Z, Han X, Li F. Blood impairs viability of fat grafts and adipose stem cells: Importance of washing in fat processing. *Aesthet Surg J.* 2021;41:86–97.

Reply: Quality and Quantity–Cultured Human Mononuclear Cells Improve the Human Fat Graft Vascularization and Survival in an In Vivo Murine Experimental Model

We thank Hua and Wei for their thoughtful questions regarding our article.[1] We have applied the quality and quantity (QQ) culture, which is a 1-week serum-free culture system based on an optimal mix of the mentioned cytokines. The culture was developed to increase the number and functionality of differentiated colony-forming endothelial progenitor cells.[2]

It is, however, not new. In in vitro experiments in 2012, Masuda et al.[2] discovered a quantitative and a qualitative enhancement (endothelial cell lineage differentiation; endothelial cell surface marker expression; vascular endothelial growth factor and hepatocyte growth factor secretion) of umbilical cord blood–derived $CD133^+$ endothelial progenitor cells after QQ culture. It was demonstrated in